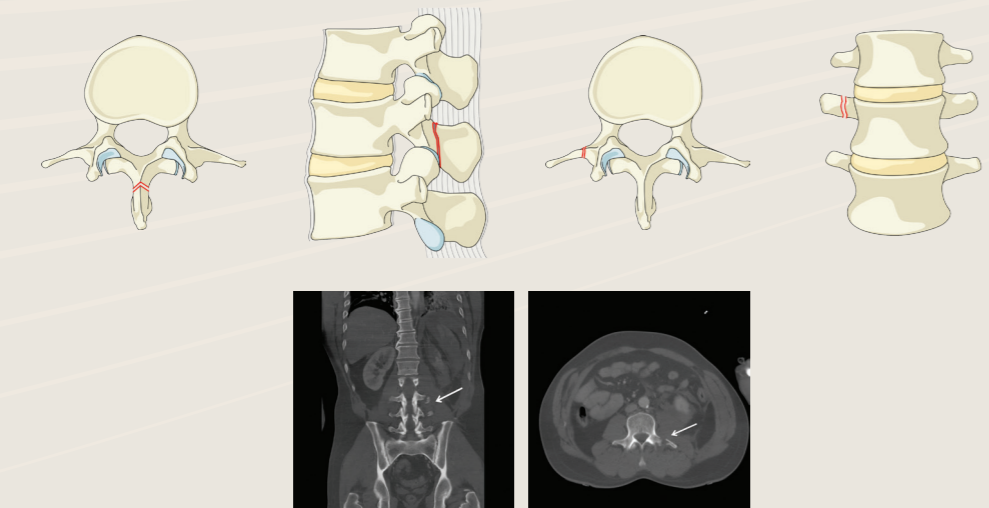


AOSpine Thoracolumbar Classification System

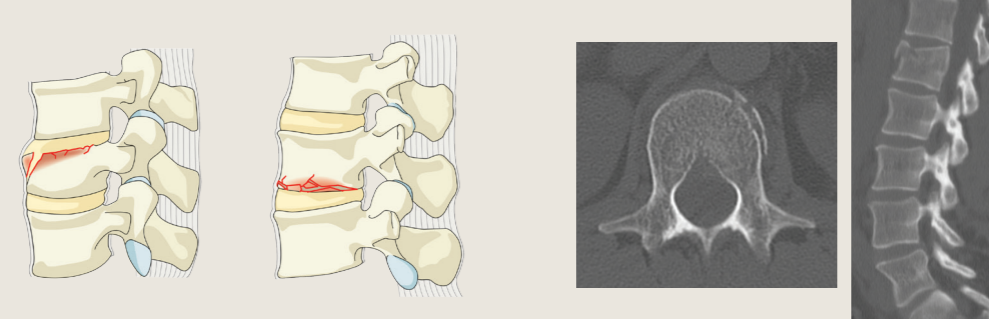
an AOSpine Knowledge Forum Trauma initiative

Type A. Compression Injuries

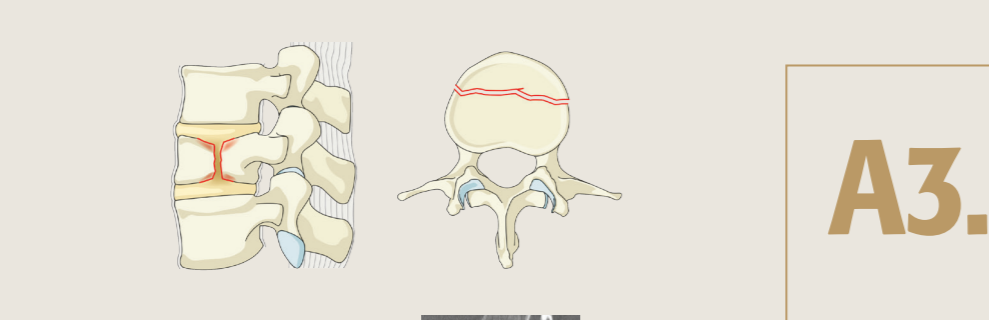
A0. Minor, nonstructural fractures
Fractures, which do not compromise the structural integrity of the spinal column such as transverse process or spinous process fractures.



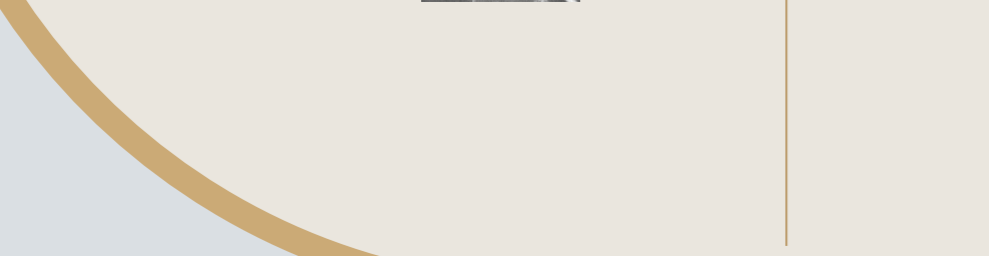
A1. Wedge-compression
Fracture of a single endplate without involvement of the posterior wall of the vertebral body.



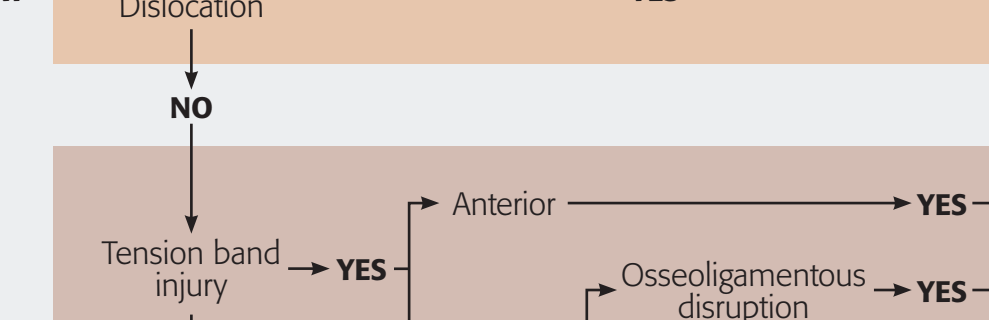
A2. Split
Fracture of both endplates without involvement of the posterior wall of the vertebral body.



A3. Incomplete burst
Fracture with any involvement of the posterior wall; only a single endplate fractured. Vertical fracture of the lamina is usually present and does not constitute a tension band failure.

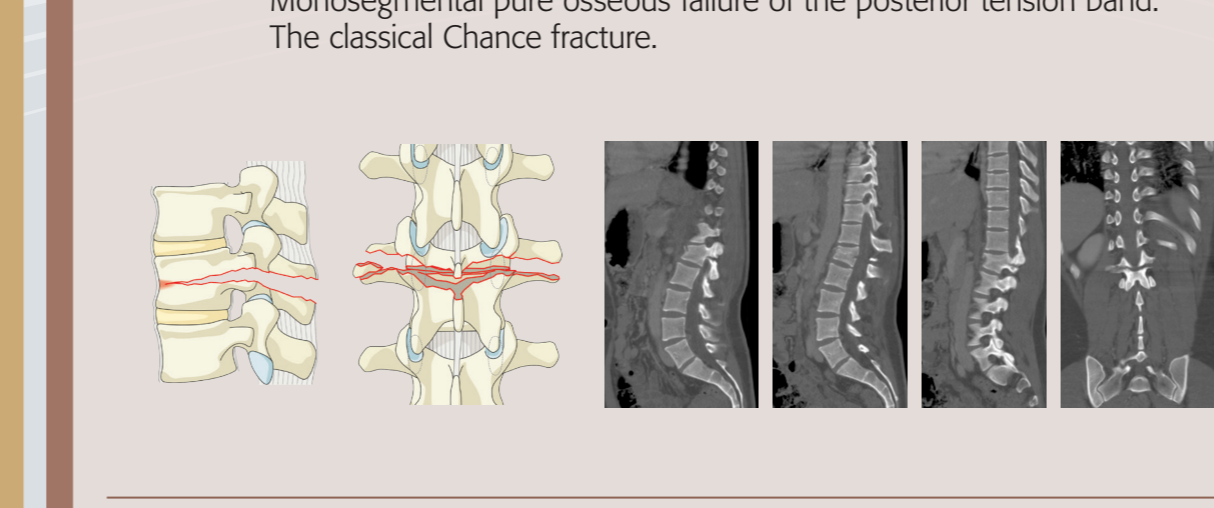


A4. Complete burst
Fracture with any involvement of the posterior wall and both endplates. Vertical fracture of the lamina is usually present and does not constitute a tension band failure.

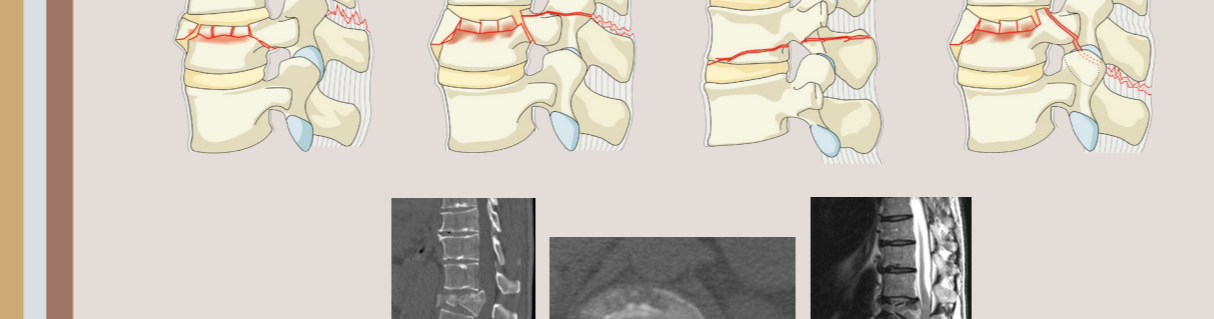


Type B. Distraction Injuries

B1. Transosseous tension band disruption Chance fracture
Monosegmental pure osseous failure of the posterior tension band. The classical Chance fracture.

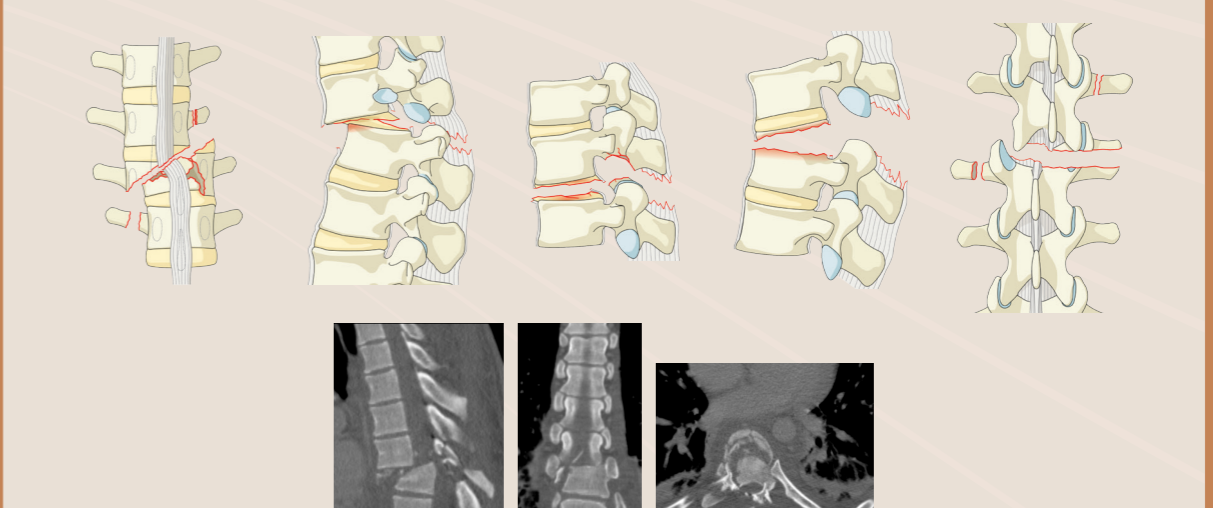


B2. Posterior tension band disruption
Bony and/or ligamentary failure of the posterior tension band together with a Type A fracture. Type A fracture should be classified separately.

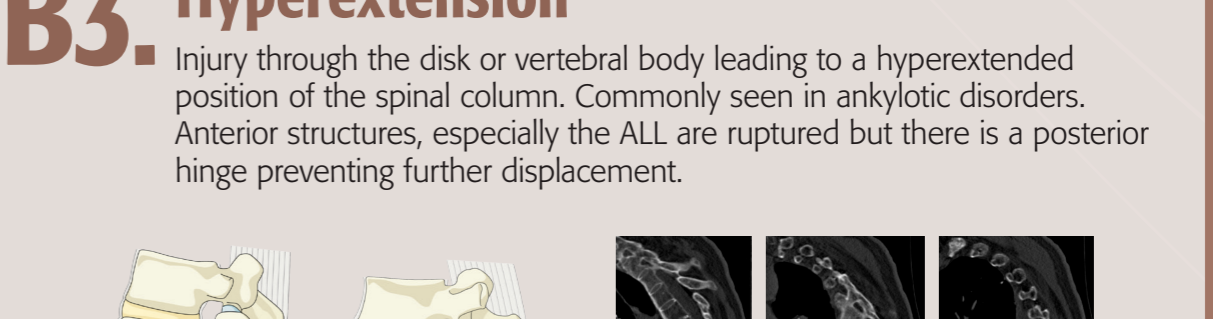


Type C. Translation Injuries

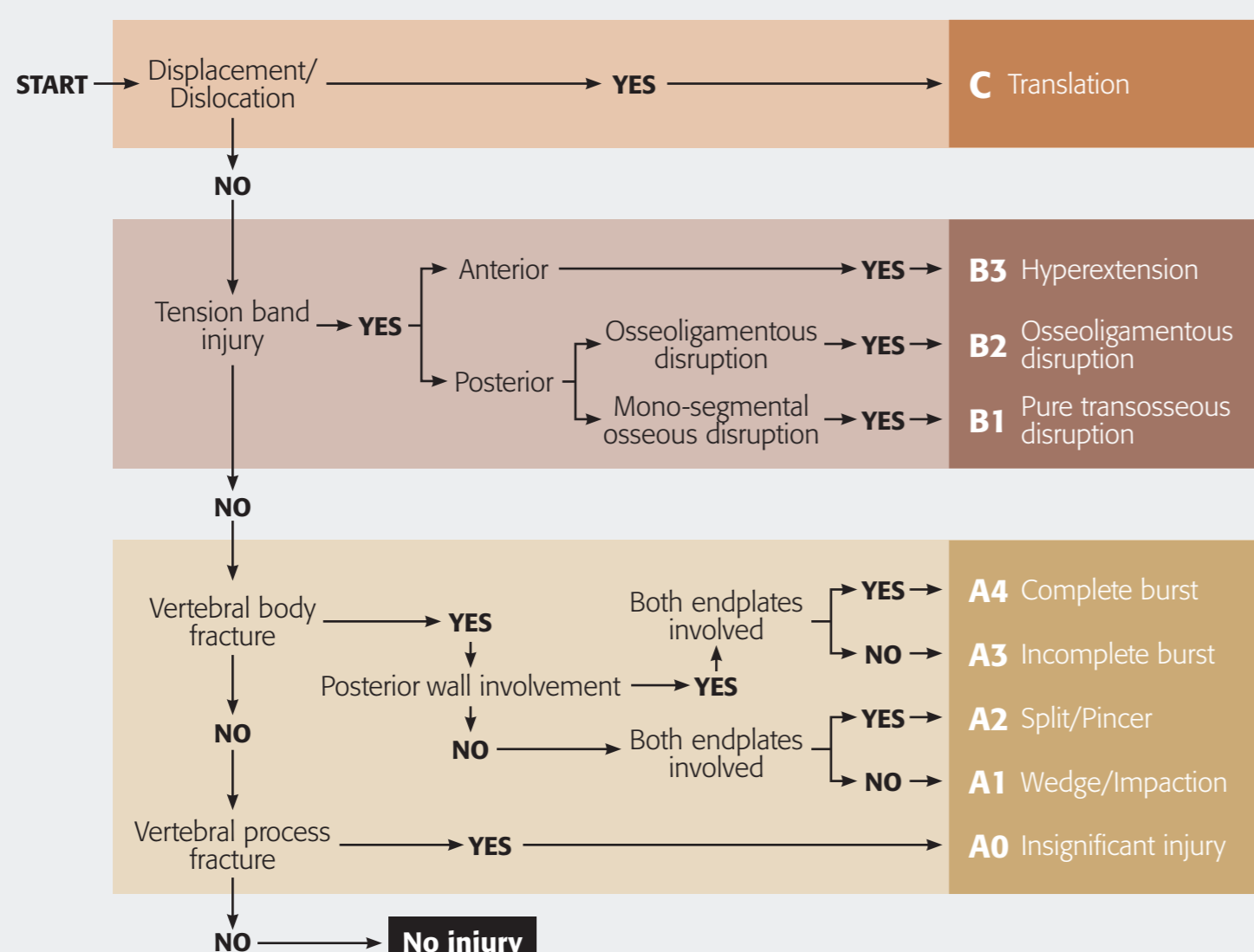
C. Displacement or dislocation
There are no subtypes because various configurations are possible due to dissociation/dislocation. Can be combined with subtypes of A or B.



B3. Hyperextension
Injury through the disk or vertebral body leading to a hyperextended position of the spinal column. Commonly seen in ankylosing disorders. Anterior structures, especially the ALL are ruptured but there is a posterior hinge preventing further displacement.



Algorithm for morphologic classification



Neurologic injury

Neurologic status at the moment of admission should be scored according to the following scheme:

Type	Description
N0	Neurologically intact
N1	Transient neurologic deficit, which is no longer present
N2	Radicular symptoms
N3	Incomplete spinal cord injury or any degree of cauda equina injury
N4	Complete spinal cord injury
NX	Neurologic status is unknown due to sedation or head injury

Modifiers

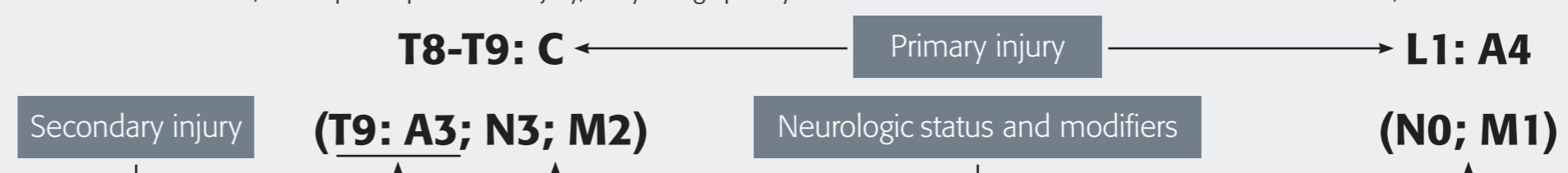
There are two modifiers, which can be used in addition to ad 1 and 2:

Type	Description
M1	This modifier is used to designate fractures with an indeterminate injury to the tension band based on spinal imaging with or without MRI. This modifier is important for designating those injuries with stable injuries from a bony standpoint for which ligamentous insufficiency may help determine whether operative stabilization is a consideration.
M2	Is used to designate a patient-specific comorbidity, which might argue either for or against surgery for patients with relative surgical indications. Examples of an M2 modifier include ankylosing spondylitis or burns affecting the skin overlying the injured spine.

Classification nomenclature

Displacement injury of the segment T8/9 with an incomplete burst fracture of T9, incomplete spinal cord injury, ankylosing spondylitis

Complete burst fracture of L1, neurologically intact, PLC status nuclear



Further information: www.aospine.org/TLclassification

Disclaimer:

1. Vaccaro, A. R., C. Oner, C. K. Kepler, M. Dvorak, K. Schnake, C. Bellabarba, M. Reinhold, B. Aarabi, F. Kandziora, J. Chapman, R. Shanmuganathan, M. Fehlings, L. Vialle, A. O. S. C. Injury and F. Trauma Knowledge (2013). "AOSpine thoracolumbar spine injury classification system: fracture description, neurological status, and key modifiers." *Spine (Phila Pa 1976)* 38(23): 2028-2037.

2. Kepler, C. K., A. R. Vaccaro, J. D. Koerner, M. F. Dvorak, F. Kandziora, S. Rajasekaran, B. Aarabi, L. R. Vialle, M. G. Fehlings, G. D. Schroeder, M. Reinhold, K. J. Schnake, C. Bellabarba and F. Cumhur Oner (2015). "Reliability analysis of the AOSpine thoracolumbar spine injury classification system by a worldwide group of naive spinal surgeons." *Eur Spine J. (e-pub)*