

User guide for BOMBS (Brain Observer MicroBleed Scale):

A rating scale for brain microbleeds

Authors: G Potter, J Wardlaw, University of Edinburgh

The Brain Observer MicroBleed Scale is a classification system devised to improve levels of inter-rater agreement about the presence, number, size and location of brain microbleeds (BMBs). The use of a standard rating scale will hopefully minimise inter-observer variation, enable cross-comparison between research groups and facilitate meta-analysis of BMB studies.

The BOMBS scale was developed after testing of an initial pilot scale by two observers highlighted several common difficulties in rating BMBs, leading to inter-observer variation. These difficulties were then incorporated into a revised scale.

Brain microbleeds are most easily identified on haem-sensitive MRI sequences, also known as T2* or gradient echo (GRE). However, they may also be visible on T2-weighted images, especially if they are numerous. T2-weighted images are particularly useful for demonstrating flow voids in cortical vessels, which can mimic BMBs (see later). If there are no BMBs evident on the GRE images, it is unlikely that they will be identified on other sequences, although all images should be reviewed as standard practice.

The BOMBS rating scale is shown on the next page. This is followed by a more detailed description of the main sections, including a diagram of the 7 anatomical locations which must be viewed for each scan. Finally, there are examples of 'certain' and 'uncertain' BMBs and examples of common BMB mimics.

Cordonnier et al. Improving inter-observer agreement about brain microbleeds: development of the Brain Observer MicroBleed Scale (BOMBS). *Stroke* 2009; 40:94-99

Guide prepared by G Potter, J Wardlaw (Joanna.wardlaw@ed.ac.uk)

The BOMBS rating scale

Brain Observer Micro Bleed Scale (BOMBS)

Date of MRI ___ / ___ / ___ Date of birth ___ / ___ / ___ Study ID _____

Are there any BMBs* ?

No → Stop

Yes ↓

Are there 1-2 BMBs?

Yes → **Beware common BMB rating problems:**

No ↓

Uncertain about any BMBs? Yes → **Beware common BMB rating problems:**

No → Rate

Beware common BMB rating problems:

- Flow voids in small cortical vessels [check T2/FLAIR]
- Hypointensity at site of deep perforators from proximal MCA
- Symmetrical hypointensity in globi pallidi [check CT: calcium?]
- Rate as 'uncertain' if pale or in a position susceptible to partial volume effects [adjacent to petrous temporal bone or orbit]
- Beware rating only 1 or 2 BMBs <5mm ['uncertain' if in doubt]

	Right		Left	
	Certain	Uncertain	Certain	Uncertain
▶ Cortex / grey-white junction¹				
Number of BMBs <5mm	<input type="text"/>	<input type="text"/>	<input type="text"/>	<input type="text"/>
Number of BMBs 5-10mm	<input type="text"/>	<input type="text"/>	<input type="text"/>	<input type="text"/>
▶ Subcortical white matter²				
Number of BMBs <5mm	<input type="text"/>	<input type="text"/>	<input type="text"/>	<input type="text"/>
Number of BMBs 5-10mm	<input type="text"/>	<input type="text"/>	<input type="text"/>	<input type="text"/>
▶ Basal ganglia grey matter³				
Number of BMBs <5mm	<input type="text"/>	<input type="text"/>	<input type="text"/>	<input type="text"/>
Number of BMBs 5-10mm	<input type="text"/>	<input type="text"/>	<input type="text"/>	<input type="text"/>
▶ Internal and external capsule				
Number of BMBs <5mm	<input type="text"/>	<input type="text"/>	<input type="text"/>	<input type="text"/>
Number of BMBs 5-10mm	<input type="text"/>	<input type="text"/>	<input type="text"/>	<input type="text"/>
▶ Thalamus				
Number of BMBs <5mm	<input type="text"/>	<input type="text"/>	<input type="text"/>	<input type="text"/>
Number of BMBs 5-10mm	<input type="text"/>	<input type="text"/>	<input type="text"/>	<input type="text"/>
▶ Brainstem				
Number of BMBs <5mm	<input type="text"/>	<input type="text"/>	<input type="text"/>	<input type="text"/>
Number of BMBs 5-10mm	<input type="text"/>	<input type="text"/>	<input type="text"/>	<input type="text"/>
▶ Cerebellum				
Number of BMBs <5mm	<input type="text"/>	<input type="text"/>	<input type="text"/>	<input type="text"/>
Number of BMBs 5-10mm	<input type="text"/>	<input type="text"/>	<input type="text"/>	<input type="text"/>

* Small, homogeneous, round foci of low signal intensity on T2*-weighted images of less than 10 mm in diameter. Low signal on T2* within infarcts or haemorrhagic strokes are not counted as BMBs.
¹ Includes subcortical BMBs that touch the grey-white matter junction.
² Includes periventricular white matter and deep portions of the centrum semiovale
³ Caudate and lentiform nuclei.

This diagram was prepared by the BOMBS authors, but appears in the publication in Stroke (2009; 40:94099) and is copyright to Stroke.

Cordonnier et al. Improving inter-observer agreement about brain microbleeds: development of the Brain Observer MicroBleed Scale (BOMBS). Stroke 2009; 40:94-99

Guide prepared by G Potter, J Wardlaw (Joanna.wardlaw@ed.ac.uk)

Description of BOMBS

The top section of the scale (yellow) consists of a flow chart, highlighting the two main situations in which common problems should be reviewed: 1. If the lesion is in a location where 'BMB mimics' are common - basal ganglia (at site of deep MCA perforators), cortex and adjacent to petrous apex / orbit (see examples below) and 2. If there are 1-2 BMBs.

Brain Observer Micro Bleed Scale (BOMBS)

Date of MRI ___ / ___ / ___ Date of birth ___ / ___ / ___ Study ID _____

Are there any BMBs* ?

No → Stop

Yes ↓

Are there 1-2 BMBs?

Yes → Beware common BMB rating problems:

No ↓

Uncertain about any BMBs?

Yes → Beware common BMB rating problems:

No → Rate

Beware common BMB rating problems:

- Flow voids in small cortical vessels [check T2/FLAIR]
- Hypointensity at site of deep perforators from proximal MCA
- Symmetrical hypointensity in globi pallidi [check CT: calcium?]
- Rate as 'uncertain' if pale or in a position susceptible to partial volume effects [adjacent to petrous temporal bone or orbit]
- Beware rating only 1 or 2 BMBs <5mm ['uncertain' if in doubt]

	Right		Left	
	Certain	Uncertain	Certain	Uncertain
► Cortex / grey-white junction¹				
Number of BMBs <5mm	<input type="checkbox"/>	<input type="checkbox"/>	<input type="checkbox"/>	<input type="checkbox"/>
Number of BMBs 5-10mm	<input type="checkbox"/>	<input type="checkbox"/>	<input type="checkbox"/>	<input type="checkbox"/>
► Subcortical white matter²				
Number of BMBs <5mm	<input type="checkbox"/>	<input type="checkbox"/>	<input type="checkbox"/>	<input type="checkbox"/>
Number of BMBs 5-10mm	<input type="checkbox"/>	<input type="checkbox"/>	<input type="checkbox"/>	<input type="checkbox"/>
► Basal ganglia grey matter³				
Number of BMBs <5mm	<input type="checkbox"/>	<input type="checkbox"/>	<input type="checkbox"/>	<input type="checkbox"/>
Number of BMBs 5-10mm	<input type="checkbox"/>	<input type="checkbox"/>	<input type="checkbox"/>	<input type="checkbox"/>
► Internal and external capsule				
Number of BMBs <5mm	<input type="checkbox"/>	<input type="checkbox"/>	<input type="checkbox"/>	<input type="checkbox"/>
Number of BMBs 5-10mm	<input type="checkbox"/>	<input type="checkbox"/>	<input type="checkbox"/>	<input type="checkbox"/>
► Thalamus				
Number of BMBs <5mm	<input type="checkbox"/>	<input type="checkbox"/>	<input type="checkbox"/>	<input type="checkbox"/>
Number of BMBs 5-10mm	<input type="checkbox"/>	<input type="checkbox"/>	<input type="checkbox"/>	<input type="checkbox"/>
► Brainstem				
Number of BMBs <5mm	<input type="checkbox"/>	<input type="checkbox"/>	<input type="checkbox"/>	<input type="checkbox"/>
Number of BMBs 5-10mm	<input type="checkbox"/>	<input type="checkbox"/>	<input type="checkbox"/>	<input type="checkbox"/>
► Cerebellum				
Number of BMBs <5mm	<input type="checkbox"/>	<input type="checkbox"/>	<input type="checkbox"/>	<input type="checkbox"/>
Number of BMBs 5-10mm	<input type="checkbox"/>	<input type="checkbox"/>	<input type="checkbox"/>	<input type="checkbox"/>

* Small, homogeneous, round foci of low signal intensity on T2*-weighted images of less than 10 mm in diameter. Low signal on T2* within infarcts or haemorrhagic strokes are not counted as BMBs.

¹ Includes subcortical BMBs that touch the grey-white matter junction.

² Includes periventricular white matter and deep portions of the centrum semiovale

³ Caudate and lentiform nuclei.

This diagram was prepared by the BOMBS authors, but appears in the publication in Stroke (2009; 40:94099) and is copyright to Stroke.

Cordonnier et al. Improving inter-observer agreement about brain microbleeds: development of the Brain Observer MicroBleed Scale (BOMBS). Stroke 2009; 40:94-99

Guide prepared by G Potter, J Wardlaw (Joanna.wardlaw@ed.ac.uk)

There are 7 locations which must be assessed on both sides of the brain. Descriptions of 3 of these (yellow) are given at the bottom of the scale as shown. The diagram on the next page demonstrates these locations.

Brain Observer Micro Bleed Scale (BOMBS)

Date of MRI ___ / ___ / ___ Date of birth ___ / ___ / ___ Study ID _____

Are there any BMBs* ? No → Stop

Yes ↓

Are there 1-2 BMBs? Yes → [Beware common BMB rating problems:]

No ↓

Uncertain about any BMBs? Yes → [Beware common BMB rating problems:]

No → Rate

Beware common BMB rating problems:

- Flow voids in small cortical vessels [check T2/FLAIR]
- Hypointensity at site of deep perforators from proximal MCA
- Symmetrical hypointensity in globi pallidi [check CT: calcium?]
- Rate as 'uncertain' if pale or in a position susceptible to partial volume effects [adjacent to petrous temporal bone or orbit]
- Beware rating only 1 or 2 BMBs <5mm ['uncertain' if in doubt]

	Right		Left	
	Rate	Rate	Rate	Rate
	Certain	Uncertain	Certain	Uncertain
▶ Cortex / grey-white junction¹				
Number of BMBs <5mm	<input type="checkbox"/>	<input type="checkbox"/>	<input type="checkbox"/>	<input type="checkbox"/>
Number of BMBs 5-10mm	<input type="checkbox"/>	<input type="checkbox"/>	<input type="checkbox"/>	<input type="checkbox"/>
▶ Subcortical white matter²				
Number of BMBs <5mm	<input type="checkbox"/>	<input type="checkbox"/>	<input type="checkbox"/>	<input type="checkbox"/>
Number of BMBs 5-10mm	<input type="checkbox"/>	<input type="checkbox"/>	<input type="checkbox"/>	<input type="checkbox"/>
▶ Basal ganglia grey matter³				
Number of BMBs <5mm	<input type="checkbox"/>	<input type="checkbox"/>	<input type="checkbox"/>	<input type="checkbox"/>
Number of BMBs 5-10mm	<input type="checkbox"/>	<input type="checkbox"/>	<input type="checkbox"/>	<input type="checkbox"/>
▶ Internal and external capsule				
Number of BMBs <5mm	<input type="checkbox"/>	<input type="checkbox"/>	<input type="checkbox"/>	<input type="checkbox"/>
Number of BMBs 5-10mm	<input type="checkbox"/>	<input type="checkbox"/>	<input type="checkbox"/>	<input type="checkbox"/>
▶ Thalamus				
Number of BMBs <5mm	<input type="checkbox"/>	<input type="checkbox"/>	<input type="checkbox"/>	<input type="checkbox"/>
Number of BMBs 5-10mm	<input type="checkbox"/>	<input type="checkbox"/>	<input type="checkbox"/>	<input type="checkbox"/>
▶ Brainstem				
Number of BMBs <5mm	<input type="checkbox"/>	<input type="checkbox"/>	<input type="checkbox"/>	<input type="checkbox"/>
Number of BMBs 5-10mm	<input type="checkbox"/>	<input type="checkbox"/>	<input type="checkbox"/>	<input type="checkbox"/>
▶ Cerebellum				
Number of BMBs <5mm	<input type="checkbox"/>	<input type="checkbox"/>	<input type="checkbox"/>	<input type="checkbox"/>
Number of BMBs 5-10mm	<input type="checkbox"/>	<input type="checkbox"/>	<input type="checkbox"/>	<input type="checkbox"/>

* Small, homogeneous, round foci of low signal intensity on T2*-weighted images of less than 10 mm in diameter. Low signal on T2* within infarcts or haemorrhagic strokes are not counted as BMBs.

¹ Includes subcortical BMBs that touch the grey-white matter junction.

² Includes periventricular white matter and deep portions of the centrum semiovale.

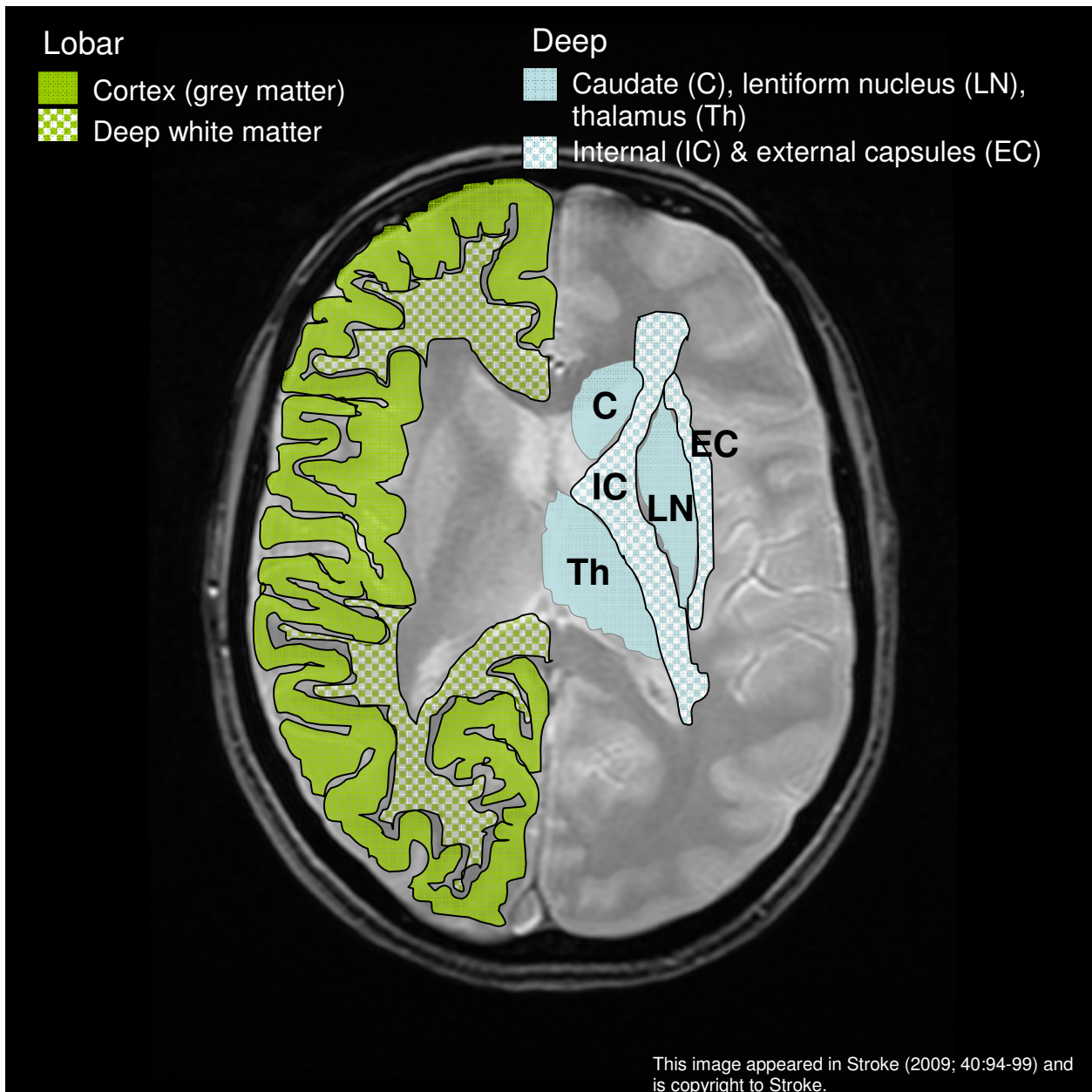
³ Caudate and lentiform nuclei.

This diagram was prepared by the BOMBS authors, but appears in the publication in Stroke (2009; 40:94099) and is copyright to

Cordonnier et al. Improving inter-observer agreement about brain microbleeds: development of the Brain Observer MicroBleed Scale (BOMBS). Stroke 2009; 40:94-99

Guide prepared by G Potter, J Wardlaw (Joanna.wardlaw@ed.ac.uk)

Locations to be assessed in BOMBS (excluding cerebellum and brainstem)



The following slides show MR images which have been chosen to demonstrate examples of 'certain' and 'uncertain' microbleeds.

BOMBS improved inter-rater reliability when all brain locations were analyzed together, and particularly in lobar locations, which had been identified in our pilot study as a difficult part of the Cordonnier et al. Improving inter-observer agreement about brain microbleeds: development of the Brain Observer MicroBleed Scale (BOMBS). Stroke 2009; 40:94-99

Guide prepared by G Potter, J Wardlaw (Joanna.wardlaw@ed.ac.uk)

brain to rate (Table 2). Although the consideration of BMB mimics is widely recognized as being important, observer variation persists, even when mimics are carefully thought about during MR scan review. BOMBS had its main effect by differentiating 'certain' BMBs from 'uncertain' BMBs – uncertainty about BMBs may be an important problem, because it applied to between one third to one half of BMBs in this study (Table 2).

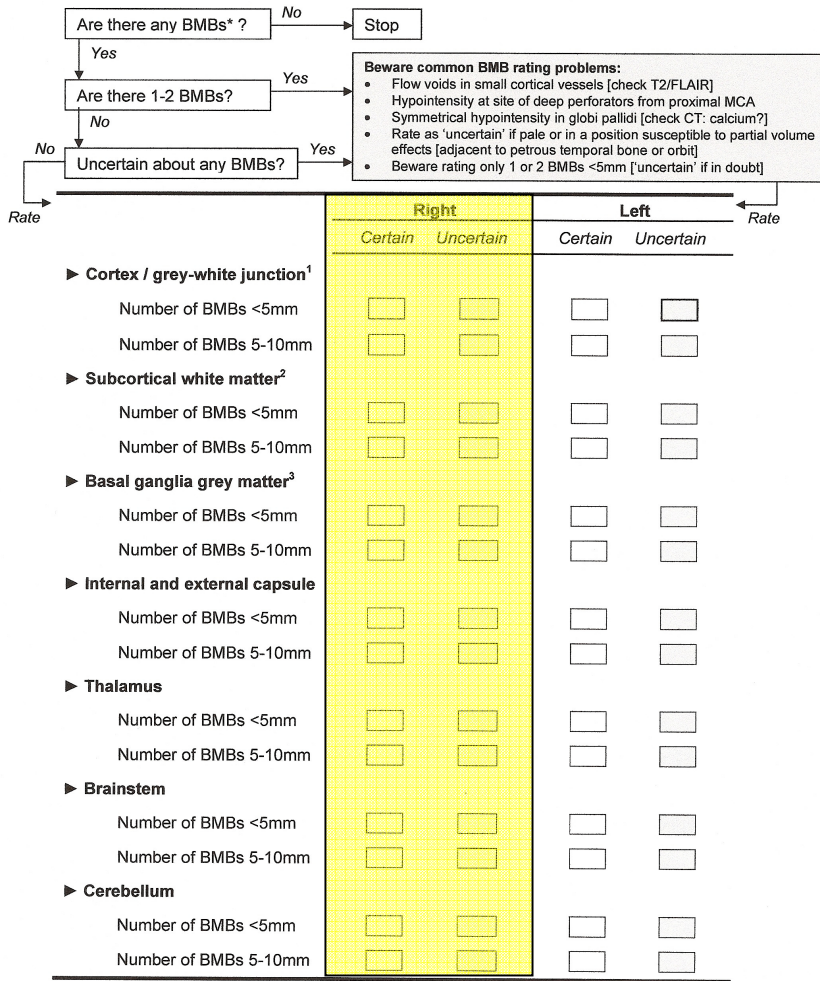
BMB maximum diameters in prior research have varied from 2-5mm, to ≤ 7 mm and ≤ 10 mm.¹ Our findings should be regarded as a baseline measure of observer agreement for future studies using BOMBS. Further work on ways of improving observer agreement about BMBs is needed, and training observers to recognize certain and uncertain BMBs, as well as their mimics, is an obvious priority (Figure 3). BOMBS will also enable others to study agreement about BMB size, number, brain location, and diagnostic certainty, as well as exploring the influence of these factors on the diagnostic and prognostic utilities of BMBs.

Note that **deep BMBs** are divided into 3 locations: **caudate head/lentiform nucleus (C, LN)**, **internal/external capsules (IC, EC)** and **thalamus (Th)**. Deep white matter BMBs which touch cortex are included in the category 'cortex/grey-white matter junction'.

Finally, BMBs should be rated as 'certain' and 'uncertain' for each side of the brain, in the appropriate row for rating size (<5mm, 5-10mm). Examples of BMBs and their common mimics are shown on the following 5 pages.

Brain Observer Micro Bleed Scale (BOMBS)

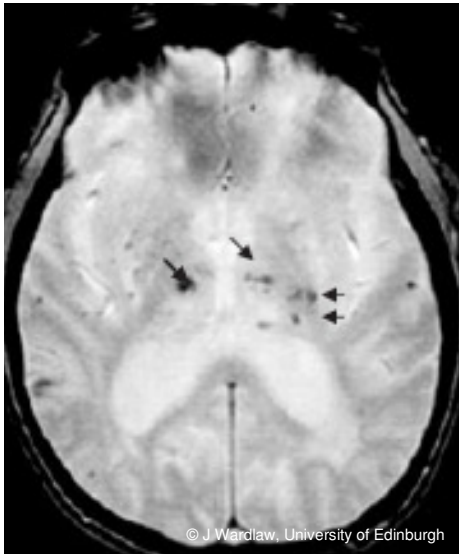
Date of MRI ___ / ___ / ___ Date of birth ___ / ___ / ___ Study ID _____



* Small, homogeneous, round foci of low signal intensity on T2*-weighted images of less than 10 mm in diameter. Low signal on T2* within infarcts or haemorrhagic strokes are not counted as BMBs.
¹ Includes subcortical BMBs that touch the grey-white matter junction.
² Includes periventricular white matter and deep portions of the centrum semiovale
³ Caudate and lentiform nuclei.

This diagram was prepared by the BOMBS authors, but appears in the publication in Stroke (2009; 40:94099) and is copyright

'Certain' BMBs



Locations with BMBs:

Cortex/grey-white matter junction (both sides)

Internal capsule/external capsule (left)

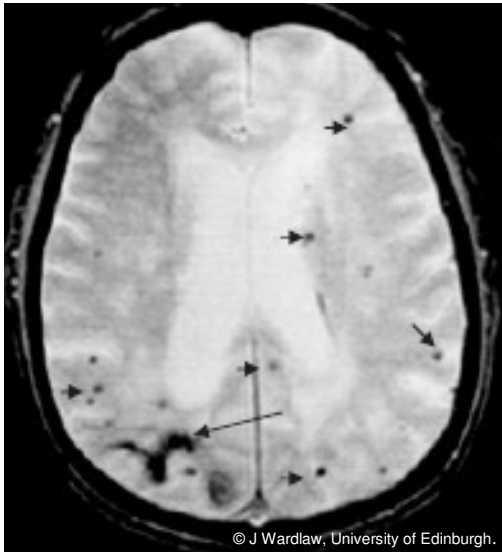Thalamus (both sides)

Note: Right thalamus BMB measures 5-10mm

Cordonnier et al. Improving inter-observer agreement about brain microbleeds: development of the Brain Observer MicroBleed Scale (BOMBS). *Stroke* 2009; 40:94-99

Guide prepared by G Potter, J Wardlaw (Joanna.wardlaw@ed.ac.uk)

'Certain' BMBs



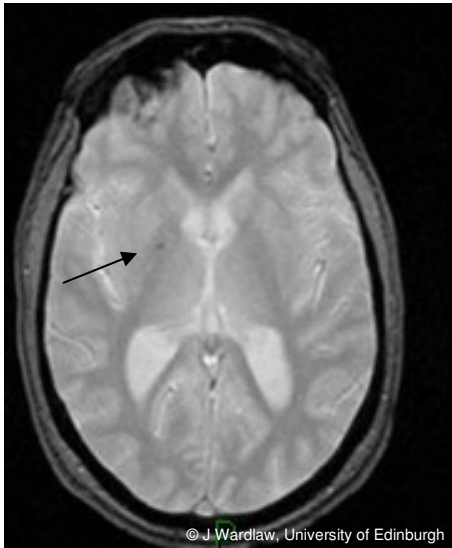
Locations: Cortex/grey-white matter junction (both sides)
Deep white matter (both sides)

Note: All BMBs (not all labelled) measure <5mm – however, there is also an old right parietal haemorrhage (long arrow)

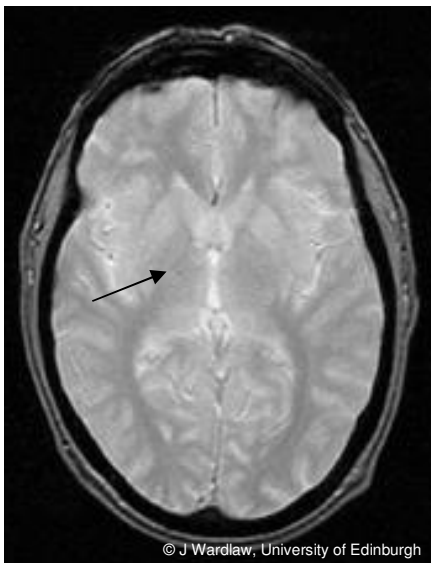
Cordonnier et al. Improving inter-observer agreement about brain microbleeds: development of the Brain Observer MicroBleed Scale (BOMBS). *Stroke* 2009; 40:94-99

Guide prepared by G Potter, J Wardlaw (Joanna.wardlaw@ed.ac.uk)

'Uncertain' BMBs



Here, there is a pale unilateral low signal lesion in the right internal capsule. In this case, no CT was available to check for asymmetric calcification. This lesion would be rated as 'uncertain'.



Here, the lesion is smaller and even paler than in the previous case and would therefore be rated as 'uncertain'.

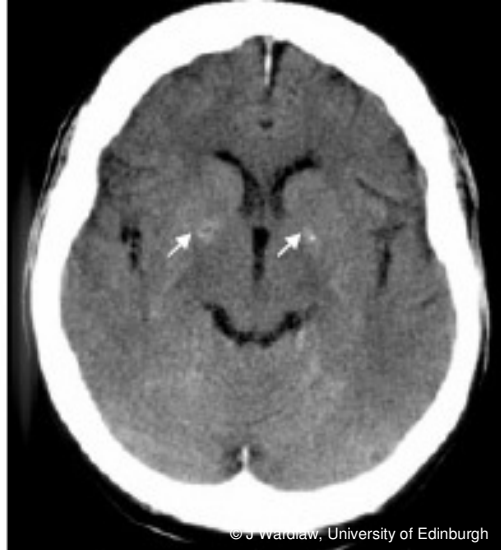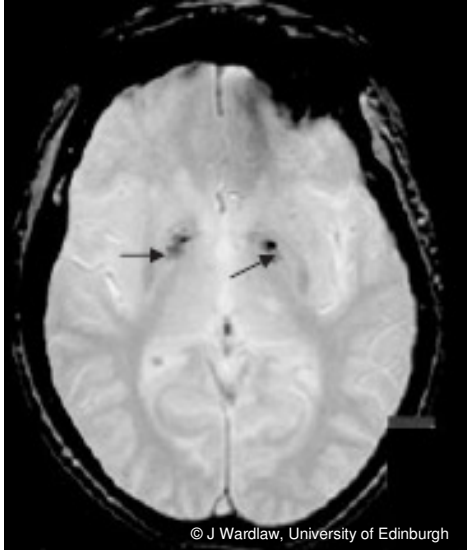
Remember that when there are 1-2 BMBs, rating may be more difficult.

Cordonnier et al. Improving inter-observer agreement about brain microbleeds: development of the Brain Observer MicroBleed Scale (BOMBS). *Stroke* 2009; 40:94-99

Guide prepared by G Potter, J Wardlaw (Joanna.wardlaw@ed.ac.uk)

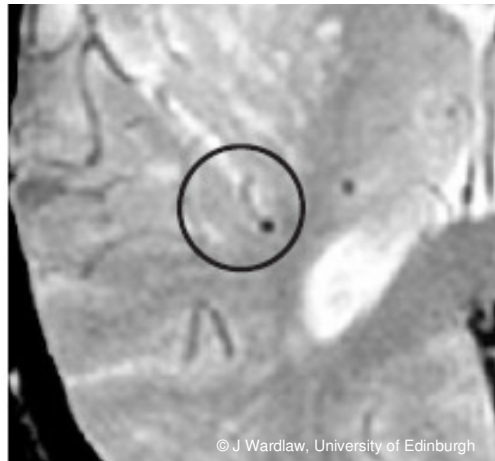
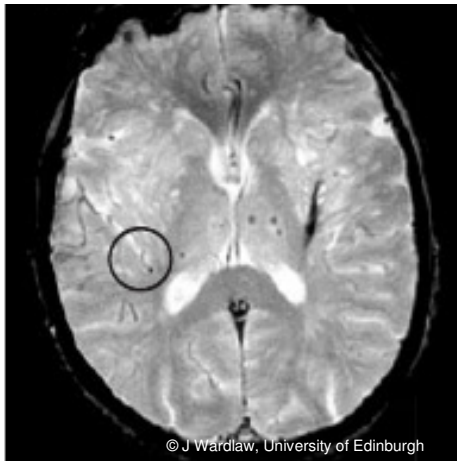Examples of common 'BMB mimics'

1. Basal ganglia calcification



In this case, axial non-contrast CT (right) confirms the presence of bilateral basal calcification, mimicking BMBs on gradient echo MRI (left)

2. Cortical vessels



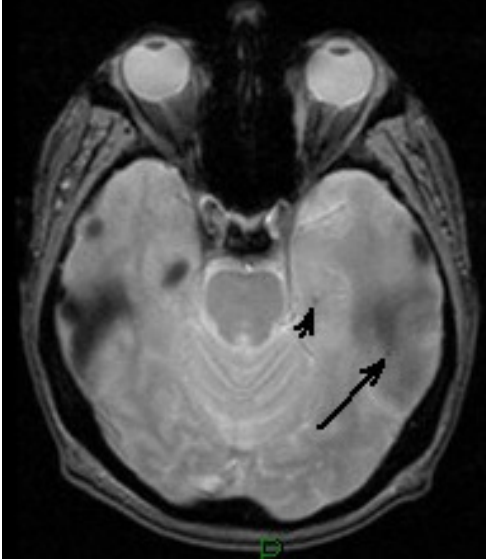
In this case, the circled 'BMB' (magnified image on right) is due to a sulcal vessel seen in cross section - with a visible vessel leading up to it.

Cordonnier et al. Improving inter-observer agreement about brain microbleeds: development of the Brain Observer MicroBleed Scale (BOMBS). *Stroke* 2009; 40:94-99

Guide prepared by G Potter, J Wardlaw (Joanna.wardlaw@ed.ac.uk)

3. Partial volume artefact

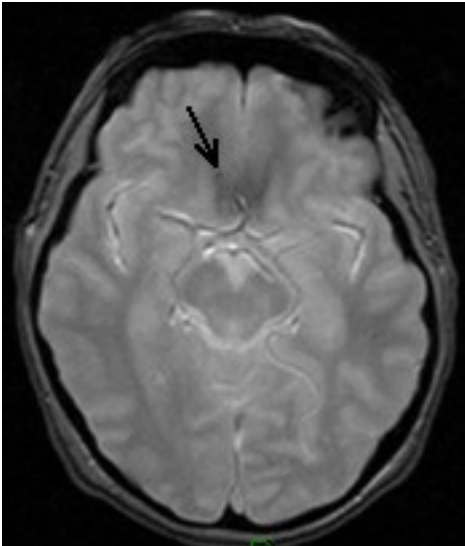
A. From petrous temporal bone



This image appeared in Stroke (2009; 40:94099) and is copyright to Stroke.

Note the small apparent 'pale' BMBs in the left temporal lobe (arrows) – these are due to partial volume from the petrous temporal bone and therefore not BMBs.

B. From orbit



This image appeared in Stroke (2009; 40:94099) and is copyright to Stroke.

Similarly, this 'pale BMB' in the right medial frontal lobe (arrow) is due to partial volume artifact from the orbit, which lies immediately inferior to this slice.

Cordonnier et al. Improving inter-observer agreement about brain microbleeds: development of the Brain Observer MicroBleed Scale (BOMBS). Stroke 2009; 40:94-99

Guide prepared by G Potter, J Wardlaw (Joanna.wardlaw@ed.ac.uk)

Conclusion

Because the clinical implications of BMBs remain to be established, there is still an opportunity to improve the reliability of BMB assessment by the use (and further development) of the BOMBS rating scale, so that adequately-powered, well-designed studies will be able to answer the outstanding clinical concerns about their diagnostic and prognostic value, and whether presence of BMBs should influence the prescription of antiplatelet, anticoagulant, or thrombolytic drugs.

Cordonnier et al. Improving inter-observer agreement about brain microbleeds: development of the Brain Observer MicroBleed Scale (BOMBS). *Stroke* 2009; 40:94-99

Guide prepared by G Potter, J Wardlaw (Joanna.wardlaw@ed.ac.uk)